

Significance of the Reticulocyte Count

Margi Sirois, EdD, MS, CVT, LAT, VTES

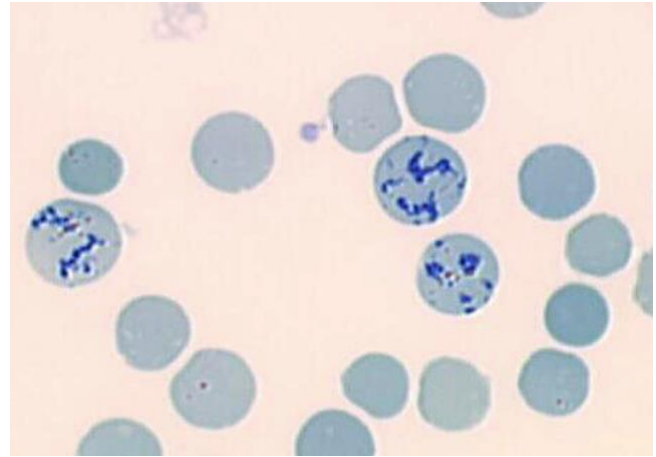
Reticulocyte counts were traditionally only performed on animals with anemia to aid in classifying the anemia as regenerative or non-regenerative. In recent years, however, research has indicated that obtaining a reticulocyte count and additional reticulocyte indices as a routine part of the complete blood count can provide valuable information even in the absence of anemia. While the reticulocyte count can be performed manually, this method is tedious and time consuming and subject to errors in interpretation. Advances in flow cytometry have allowed for accurate enumeration of reticulocytes as well as evaluation of indices such as reticulocyte volume (MCVr) and distribution width (RDWr). These additional parameters provide significant additional information to guide the diagnostic and therapeutic plan.

Prevalence of Reticulocytosis

Under normal circumstances, once the nucleus is extruded from the metarubricyte, the resulting reticulocyte continues to mature in the bone marrow for 48-72 hours. Some of these cells may be released from the bone marrow after 48 hours and continue to mature in the peripheral circulation. Reticulocytosis indicates an underlying disease process causing a bone marrow response. When the bone marrow begins to respond to a disease process that influences erythropoiesis, some of the younger, larger reticulocytes may also be released. Even when anemia is present, the hemogram of the peripheral blood may not indicate expected changes.

Summary

When present, reticulocytosis can be an early indicator of a variety of underlying diseases or can help identify anemia when the peripheral blood CBC does not reflect the underlying disease process. Diagnosis of conditions affecting the cardiac or respiratory system, gastrointestinal disease, inflammatory disorders, neoplasia, and portosystemic shunt can be aided with evaluation of reticulocyte count and indices. The reticulocyte count is a sensitive and specific indicator of bone marrow response. Automated analysis of reticulocyte numbers and indices is an objective indicator to aid in classifying anemia as regenerative or non-regenerative as well as identifying potential underlying disease in the absence of anemia.



Reticulocytes in canine peripheral blood smear

Anemia generally manifests as visible polychromasia and anisocytosis on the peripheral blood smear. However, this may not be evident if the patient's normal compensatory mechanisms have already addressed the need for increased oxygen-carrying capacity. In addition, some conditions (i.e. IMHA) may present with mixed anisocytosis with both microcytic spherocytes and polychromatic macrocytes, so a change in MCV may also not be evident on the hemogram. Data suggest that as many as 37% of patients can have normal results on the CBC with reticulocytosis that reflects an underlying disorder.

1. Walker HK, Hall WD, Hurst JW, editors. Clinical Methods: The History, Physical, and Laboratory Examinations. 3rd edition. [Butterworths](#), Boston: 1990.
2. Hodges, J, Christopher, M. Diagnostic accuracy of using erythrocyte indices and polychromasia to identify regenerative anemia in dogs. JAVMA 2011; 238(11): 1452-1468
3. Pattullo KM¹, Kidney BA, [Taylor SM](#), Jackson ML. Reticulocytosis in nonanemic dogs: increasing prevalence and potential etiologies. Vet Clin Pathol. 2015 Mar;44(1):26-36. doi: 10.1111/vcp.12215. Epub 2014 Dec 8.